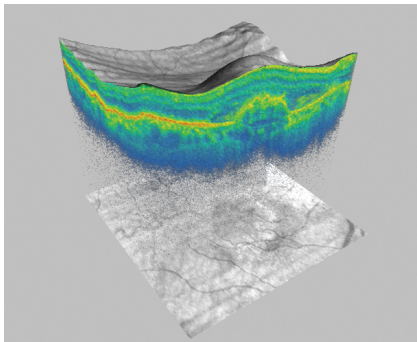


Advanced RPE Analysis with ZEISS CIRRUS



Seeing beyond



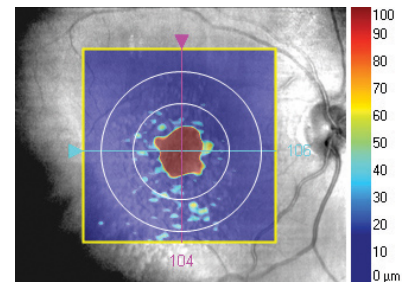
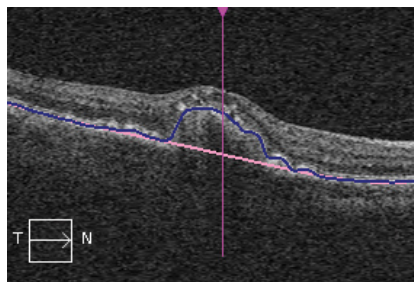
Assess the integrity of and potential changes to the RPE layer in patients with age-related macular degeneration (AMD)

- High-density, cross-sectional visualization of RPE elevations.
- Identification of the fovea location and areas where the RPE is missing or thinning.
- Automatic quantitative measurements.
- Side-by-side comparisons of prior and current visit to track disease progression.
- Standard macular 512x128 or 200x200 cubes, including existing patient data.

How does CIRRUS® from ZEISS analyze the RPE?

RPE elevations

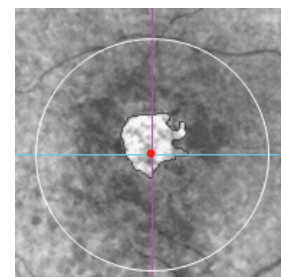
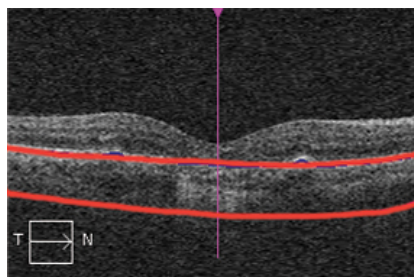
If the RPE is raised above a baseline plane, a new proprietary algorithm for CIRRUS maps and measures the area and volume of the elevations.



RPE Elevations	Prior	Current	Differences	% Change
Area in 3 mm Circle (mm ²)	2.9	0.7	-2.2	-75.9%
Area in 5 mm Circle (mm ²)	3.5	1.7	-1.8	-51.4%
Volume in 3 mm Circle (mm ³)	0.41	0.03	-0.38	-92.7%
Volume in 5 mm Circle (mm ³)	0.43	0.06	-0.37	-86.0%

Sub-RPE illumination

If the RPE is absent or has lost integrity, the OCT beam penetrates into the choroid. A new proprietary algorithm for CIRRUS can determine when this occurs, CIRRUS then maps and measures the affected area.



Sub-RPE Illumination	Prior	Current	Differences	% Change
Area in 5 mm Circle (mm ²)	0.0	1.3	1.3	xxx
Closest distance to Fovea (mm)	xxx	0.0	xxx	xxx

Literature on SD-OCT for RPE Analysis

RPE atrophy or thinning

SD-OCT can identify and quantitate areas of GA. The size and shape of these areas correlate well with the areas of GA seen on autofluorescence images; however, SD-OCT imaging also provides important cross-sectional anatomic information.¹

Lesion size is precisely determinable by SD-OCT, and foveal involvement is more accurate by SD-OCT than by FAF.³

Evaluation of foveal sparing was superior with the SD-OCT systems than FAF. This might be due to the fact that in SD-OCT the complete volume of the macula can be evaluated and therefore the precise evaluation of the fovea is easier than in the grey scale FAF image.⁵

RPE elevations

An appreciation of the quantitative changes in drusen volume over time using SD-OCT imaging provides a novel strategy for following normal disease progression and for identifying novel clinical trial end points to be used when investigating therapies for the treatment of non-exudative AMD.⁶

The results of this pilot study show that SD-OCT can be an important tool in measuring the extent of drusen and offers the potential for greater precision and efficiency than does CFP [color fundus photography].⁸

References

1. Lujan BJ, Rosenfeld PJ, Gregori G, Wang F, Knighton RW, Feuer WJ, Puliafito CA. Spectral domain optical coherence tomographic imaging of geographic atrophy. *Ophthalmic Surg Lasers Imaging*, 2009 Mar-Apr;40(2):96-101.
2. Yehoshua Z, Rosenfeld PJ, Gregori G, Feuer WJ, Falcão M, Lujan BJ, Puliafito C. Progression of geographic atrophy in age-related macular degeneration imaged with spectral domain optical coherence tomography. *Ophthalmology*, 2011 Apr;118(4):679-86. Epub 2010 Oct 29.
3. Sayegh RG, Simader C, Scheschy U, Montuoro A, Kiss C, Sacu S, Kreil DP, Prünke C, Schmidt-Erfurth U. A systematic comparison of spectral-domain optical coherence tomography and fundus autofluorescence in patients with geographic atrophy. *Ophthalmology*, 2011 Sep;118(9):1844-51. Epub 2011 Apr 15.
4. Yehoshua Z, Rosenfeld PJ, Gregori G, Penha F. Spectral domain optical coherence tomography imaging of dry age-related macular degeneration. *Ophthalmic Surg Lasers Imaging*, 2010 Nov-Dec;41 Suppl:S6-S14. doi: 10.3928/15428877-20101031-19.
5. U.W. Scheschy, R.G. Sayegh, C. Simander, C.G. Kiss, M. Baratsits, S. Sacu, C. Prunte, U. Schmidt-Erfurth. Evaluation of Foveal Sparing in Geographic Atrophy in Fundus Autofluorescence and Spectral-Domain Optical Coherence Tomography. 2010 ARVO Poster D664.

References

6. Yehoshua Z, Wang F, Rosenfeld PJ, Penha FM, Feuer WJ, Gregori G. Natural History of Drusen Morphology in Age-Related Macular Degeneration Using Spectral Domain Optical Coherence Tomography. *Ophthalmology*, 2011 Jul 1. [Epub ahead of print]
7. Gregori G, Wang F, Rosenfeld PJ, Yehoshua Z, Gregori NZ, Lujan BJ, Puliafito CA, Feuer WJ. Spectral domain optical coherence tomography imaging of drusen in nonexudative age-related macular degeneration. *Ophthalmology*, 2011 Jul;118(7):1373-9. Epub 2011 Mar 9.
8. Jain N, Farsiou S, Khanifar AA, Bearely S, Smith RT, Izatt JA, Toth CA. Quantitative comparison of drusen segmented on SD-OCT versus drusen delineated on color fundus photographs. *Invest Ophthalmol Vis Sci*, 2010 Oct;51(10):4875-83. Epub 2010 Apr 14.
9. PJ Rosenfeld, SR Sadda, Z Yehoshua, FM Penha, MG Nittala, RK Kunduru, G GRegori, WJ Feuer. Comparison of Drusen Area Detected by Spectral Domain OCT and Color Fundus Photography. 2011 ARVO Poster A393.
10. Schlanitz FG, Ahlers C, Sacu S, Schütze C, Rodriguez M, Schrieffl S, Golbaz I, Spalek T, Stock G, Schmidt-Erfurth U. Performance of drusen detection by spectral-domain optical coherence tomography. *Invest Ophthalmol Vis Sci*, 2010 Dec;51(12):6715-21.
11. S Sharma, S Huo, P Kaiser. Comparison of Manual versus Automated Analysis of Spectral Domain Optical Coherence Tomography (SDOCT) Scans in Non-Neovascular Age Related Macular Degeneration. 2011 ARVO Poster D795.

How to read the Advanced RPE Analysis report


Name: Prior Current

ID: Exam Date:

DOB: Exam Time:

Gender: Serial Number:

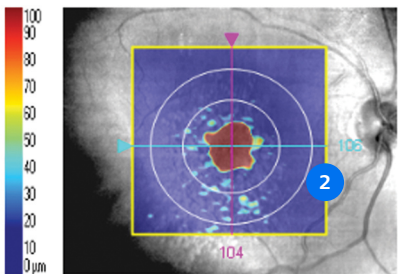
Doctor: Signal Strength:



Advanced RPE Analysis : Macular Cube 200x200

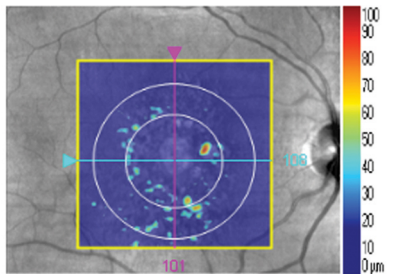
OD OS

1 **Prior Visit**



Fovea: 104, 106 50% Transparency

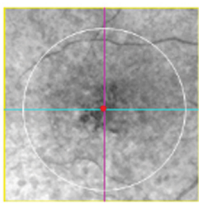
Current Visit



Fovea: 101, 108 50% Transparency

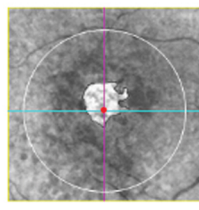
RPE Elevation Map

3



30% Transparency


4



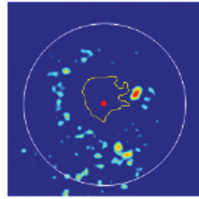
30% Transparency

Sub-RPE Slab

5



5



RPE Profile™

6

RPE Elevations	Prior	Current	Difference ^a	% Change
Area in 3 mm Circle (mm ²)	2.9	0.7	-2.2	-75.9%
Area in 5 mm Circle (mm ²)	3.5	1.7	-1.8	-51.4%
Volume in 3 mm Circle (mm ³)	0.41	0.03	-0.38	-92.7%
Volume in 5 mm Circle (mm ³)	0.43	0.06	-0.37	-86.0%
Sub-RPE Illumination	Prior	Current	Difference ^a	% Change
Area in 5 mm Circle (mm ²)	0.0	1.3	1.3	xxx
Closest distance to Fovea (mm)	xxx	0.0	xxx	xxx

^aThe calculated difference does not consider test-retest variability.

- 1** RPE Elevation Map overlaid on fundus image. Note: The minimum RPE elevation that the software will include in the quantitative result is 19.5 μm .
- 2** Circles on the RPE Elevation Map 3 mm and 5 mm in diameter, centered on the fovea location.
- 3** Fovea location coordinates.
- 4** Sub-RPE Slab, an *en face* image of the reflectivity of tissue beneath Bruch's membrane. The automatic sub-RPE illumination segmentation is shown with an outline.
- 5** RPE Profile™, a map that combines the RPE elevation map and the areas of sub-RPE illumination identified by the software, outlined in yellow.
- 6** Table of values, including assessment of change versus prior period.

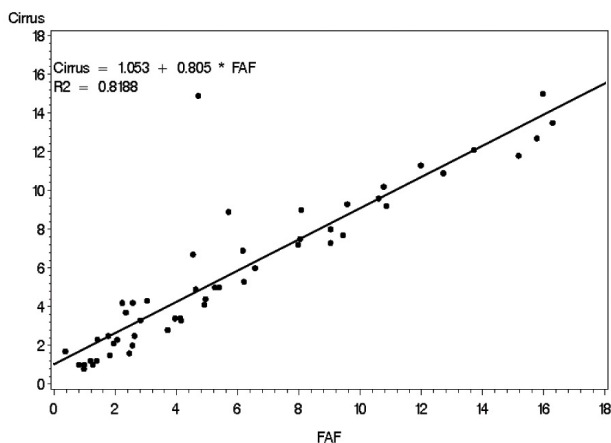
Clinical evaluation of CIRRUS Advanced RPE Analysis

Advanced RPE Analysis Study: Measurements of area of increased illumination under the RPE

To evaluate the CIRRUS OCT's method of measuring areas of sub-RPE illumination, a non-significant risk clinical study was conducted to compare the CIRRUS OCT automated measurements of the illumination area under the retinal pigment epithelium (RPE) to expert manual measurements of areas of hypofluorescence typical of geographic atrophy in fundus autofluorescence (FAF) images taken with the Spectralis HRA+OCT (Spectralis Heidelberg Retina Angiograph (HRA) and Spectralis OCT). Only subjects that were being evaluated for dry AMD with geographic atrophy and who were scheduled for FAF imaging were recruited into the study.

Four sites participated in the clinical data collection. Fifty-two eyes from 52 subjects were included in the data analysis. The mean (SD) lesion size detected in the study was 5.9 (4.5) mm² for FAF and 5.8 (4.0) mm² for OCT; the mean difference was 0.1 (1.9) mm². A paired t-test showed no significant difference between the measurements obtained by the two instruments. Regression analysis showed good correlation between FAF and OCT measurements with a slope of 0.81, an intercept of 1.05, and an R² of 0.82.

The differences between the two imaging modalities did not appear to affect the measurement outcomes. The results of the study showed that GA area measurements from expert manual segmentation of FAF images and the CIRRUS OCT automated algorithm were comparable.



Advanced RPE Analysis Study: Measurements of elevated RPE

To evaluate the CIRRUS OCT's automated method of measuring elevated RPE, a non-significant risk clinical study was conducted to compare the areas designated as elevated retinal pigment epithelium (RPE) by an automated algorithm of the CIRRUS OCT to those manually drawn by experts designated as drusen on color fundus photographs (CFPs). Subjects were 50 years of age and older with a diagnosis of dry age-related macular degeneration (AMD) with macular drusen.

Three sites participated in the clinical data collection. Seventy eyes from 70 subjects were considered for inclusion in the data analysis. The results showed that there were significant differences between the two modalities that can be explained by the fundamental differences in the technology. Drusen maps from OCT data represented significant disruptions to the RPE geometry, while color fundus photos identified abnormalities in macular pigmentation. From this study, it can be concluded that these two modalities provide complementary information that is useful for evaluating patients with age-related macular degeneration.

Notes

- RPE elevation measurements are not meant to replace other means of clinical evaluation such as color fundus photographs for drusen documentation and measurement.
- Additional information and notes are provided in the CIRRUS User Manual.

References:
Data on File at Carl Zeiss Meditec, Inc. (Dublin, CA)



Carl Zeiss Meditec, Inc.

5300 Central Parkway

Dublin, CA 94568

USA

www.zeiss.com/cirrus

en-INT_31_012_00501 CZ IV/2023 International edition: Only for sale in selected countries.

The contents of the brochure may differ from the current status of approval of the product or service offering in your country. Please contact our regional representatives for more information. Subject to changes in design and scope of delivery and due to ongoing technical development. CIRRUS and RPE Profile are either trademarks or registered trademarks of Carl Zeiss Meditec AG or other companies of the ZEISS Group in Germany and/or other countries.

© Carl Zeiss Meditec, Inc., 2023. All rights reserved.