

Early experience with the aspheric CT LUCIA 621P IOL*. Host of design features add up to reliable optical performance

By Rüdiger Schmid, MD, FEBO

The following text is based on the surgeon's own experience, combined with internal studies conducted by Carl Zeiss Meditec.

The "perfect" IOL for modern cataract surgery would predictably provide excellent visual acuity and quality of vision outcomes in routine and challenging cases. To achieve those goals, an IOL would need to be made of a highly biocompatible clear material, be easy to deliver using a preloaded injector system, center well within the capsular bag, feature a large optical zone matching the mesopic pupil size for the average cataract age patient, and have a high tolerance to the adverse effects of potential decentration.

Considering its design and our early clinical experience, the CT LUCIA 621P, a new monofocal aspheric IOL from Carl Zeiss Meditec, seems to meet these criteria.

CT LUCIA 621P DESCRIPTION

The CT LUCIA 621P is a single-piece implant with step-vaulted haptics and a 6.0 mm optic that has a sharp posterior edge and innovative aspheric design (ZEISS Optic technology), which as described below, is the most outstanding feature of this new lens.

The CT LUCIA 621P is made of a glistening-free** hydrophobic acrylic material with a heparin-coated surface***. Compared with hydrophilic acrylic IOLs, hydrophobic acrylic lenses are associated with less posterior capsule opacification and are much less prone to develop opacification.^{1,2} The development of PCO is further limited by the sharp posterior optic edge of the CT LUCIA 621P. The material of the 621P has a Abbe number of 51, indicating lower chromatic aberration resulting into better optical quality with pseudophakic lenses.³

The CT LUCIA 621P comes preloaded in a new proprietary single-use injector system (BLUESERT™) that allows for an easy and safe cataract surgery workflow. The injector is a user-friendly device designed for reproducible IOL delivery into the capsular bag through a 2.2 mm incision****. It features a silicone plunger that avoids damage to the IOL and advances with less force than needed using a previous generation injector system. A spring mechanism allows for comfortable injection resistance, and a latching of the inner section

prevents rejection once the plunger has been depressed in the front section of the cartridge.

Unfolding of the CT LUCIA 621P IOL in the capsular bag is facilitated by its heparin-coated surface***. Yet, the lens unfolds in a gentle and controlled manner that enables its positioning. The sophisticated optic-haptic junction with its relatively rigid and enlarged step-vaulted haptics socket (Figure 1) together with the length and biomechanics of the haptics act to maintain stable IOL centration.



Figure 1. Schematic illustration of the CT LUCIA 621P optic-haptic junction

ZEISS OPTIC (ZO) ASPHERICITY CONCEPT

ZEISS Optic (ZO) technology differentiates the CT LUCIA 621P from other aspheric IOLs. It combines the performance benefits of SA-correcting and SA-neutral designs in order to provide excellent image quality with a high tolerance to decentration (Figure 2).⁴

In addition, the CT LUCIA 621P optic is designed for optimum performance at pupil sizes of 4 to 5 mm, which corresponds to the pupil size of persons in the age range of most cataract patients. Aspheric IOLs with varying amounts of negative SA were introduced to compensate for positive corneal SA and thereby improve mesopic vision and contrast sensitivity relative to spherical IOLs. With decentration, however, optical quality with an SA-correcting IOL deteriorates due to an increase in coma.⁵

Thanks to the design of modern implants and with good surgical technique, postoperative IOL decentration can be minimized. Nevertheless, decentration arising

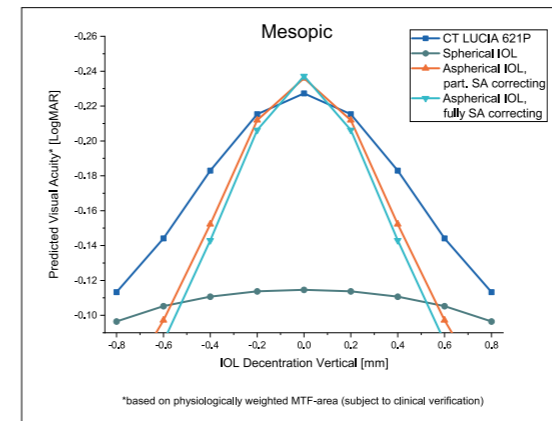


Figure 2. LogMAR predicted visual acuity in mesopic light condition vs. vertical IOL decentration****

because of a poorly sized, shaped, or positioned capsulorhexis, zonular insufficiency, or aberrant capsular contraction remains a concern considering the number and prevalence of factors that predispose to these situations. Pseudoexfoliation, which is associated with zonule weakness, difficulty with capsulorhexis creation, and capsular contraction, appears to be the most common risk factor for IOL decentration.⁶

The ZEISS Optic features a central zone (~3.5 mm) that has negative SA, balancing the positive SA of the natural cornea to optimize contrast sensitivity. Then, moving from the edge of the central zone to the periphery, the SA of the CT LUCIA 621P optic changes from negative to positive, giving the IOL improved tolerance to the negative impact of decentration on visual quality.

Findings from optical bench studies measuring visual acuity and visual quality show that the CT LUCIA 621P has better overall decentration tolerance under both photopic and mesopic conditions compared to aspheric IOLs that partially or fully compensate for SA.⁷ In addition, the CT LUCIA 621P had better peak visual acuity under mesopic conditions at myopic defocus compared with fully and partially SA-correcting aspheric IOLs.⁷ This latter finding suggests that visual acuity for patients implanted with the CT LUCIA 621P should be less impacted by post-surgery residual refraction.

CLINICAL EXPERIENCE

We have had the opportunity to use the CT LUCIA 621P IOL in our clinic since June 2020 and implanted it in 10 eyes within the first few months of its availability. Both the intraoperative experience and patient outcomes have been very positive. Delivery of the preloaded lens was very smooth using the new injector system. Although the posterior haptic appeared slightly crumpled in some cases, it recovered its normal shape within seconds thanks to the material's elasticity, and we saw no visible evidence of damage. Lens positioning was excellent, consistent with our experience using

previously available CT LUCIA IOLs (Figure 3).

We targeted a refraction of -0.5 D in most eyes implanted with the CT LUCIA 621P IOL, because in our experience this slightly myopic objective refraction is most suitable for older patients. Biometry was done with the IOLMaster 700 with total keratometry, and the Barrett True K formula was used. Good refractive predictability was achieved in this initial series of eyes. Patients were satisfied with their visual acuity and quality of vision after surgery, even in cases where the IOL seemed to be slightly decentered, which occurred mainly in relation to an irregular pupil. No patients have reported positive or negative dysphotopsia.

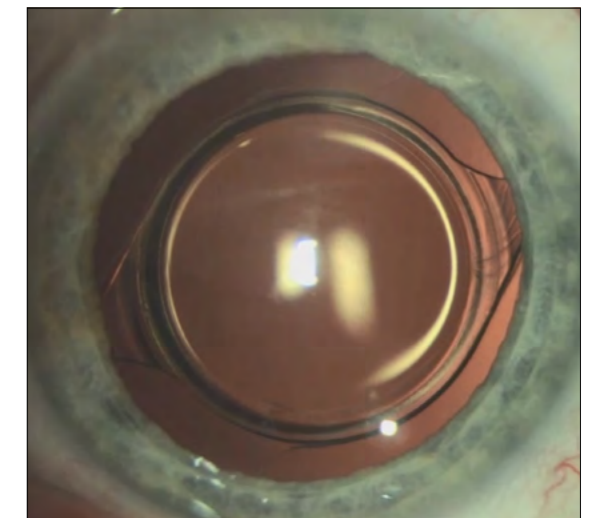


Figure 3. Slit lamp image of the well centered CT LUCIA 621P

CONCLUSION

The features of the CT LUCIA 621P IOL, including its intraoperative handling characteristics, excellent refractive predictability, stability in the capsular bag, and consistently good visual outcomes, make it a good option to use as our standard IOL for cataract surgery patients with a monofocal lens. In addition, because of the benefits of the ZEISS Optic concept, the CT LUCIA 621P IOL is now our implant of choice even in more complicated cases where there is a concern about risk for potential lens decentration.

Dr. med. Rüdiger Schmid FEBO
is Senior Consultant at accuratis. Practice
for Refractive Eye Surgery, Ulm, Germany.
Consultant to ZEISS.



en-US - 32 - 025 - 034011 - CZW12023 - United States Edition: Only for sale in selected countries. The contents of the text may differ from the current status of approval of the product or service offering in your country. Please contact our regional representatives for more information. Subject to changes in design and scope of delivery and due to ongoing technical development, CT LUCIA is either a trademark or registered trademark of Carl Zeiss Meditec AG or other companies of the ZEISS Group in Germany and / or other countries. © Carl Zeiss Meditec USA, Inc., 2023. All rights reserved. The statements of the author reflect only his personal opinion and experiences and do not necessarily reflect the opinion of any institution that he is affiliated with. The author alone is responsible for the content of his experience reported and any potential resulting arrangements. Carl Zeiss Meditec AG and its affiliates do not have clinical evidence supporting the opinions and statements of the author nor accept any responsibility or liability of the author's content. The author has a contractual or other financial relationship with Carl Zeiss Meditec Production, LLC and its affiliates and has received financial support.

* CT LUCIA 621P CE 0297 (Carl Zeiss Meditec AG)
** Clinical Study in US with CT LUCIA 61P of same material did not show any glistenings at 12 months.
*** The heparin coating on the lens surface has no pharmacological, immunological or metabolic action.
**** Incision size depending on depth: up to 2.6 mm.
***** The data is taken from a simulation. The transferability of the results of such a simulation to patients with an actual implanted intraocular lens has not yet been scientifically proven. Whether the simulated impressions correspond to the actual visual impressions must be clarified in future invasive studies.

- References
1. Li Y, Wang J, Chen Z, Tang X. Effect of hydrophobic acrylic versus hydrophilic acrylic intraocular lens on posterior capsule opacification: meta-analysis. *PLoS One*. 2013;8(11):e77864.
 2. Fernández J, Sánchez-García A, Rodríguez-Valligó M, Piñero DP. Systematic review of potential causes of intraocular lens opacification. *Clin Exp Ophthalmol*. 2020;48(1):89-97.
 3. Zhao H, Meinster MA. The effect of chromatic dispersion on pseudophakic optical performance. *Br J Ophthalmol*. 2007;91(9):1225-1229.
 4. Liu H, Brennan MA. Anatomically accurate, finite model eye for optical modeling. *J Opt Soc Am A Opt Image Sci Vis*. 1997;14(8):1684-1695.
 5. Eppig T, Scholz K, Lüffler, Mesner A. Langenbacher A. Effect of decentration and tilt on the image quality of aspheric intraocular lens designs in a model eye. *J Cataract Refract Surg*. 2009;35(6):1091-1100.
 6. Ascaso FJ, Hueva V, Gryzbowski A. Epidemiology, etiology, and prevention of late IOL-capsular bag complex dislocation: review of the literature. *J Ophthalmol*. 2015;2015:805706.
 7. Carl Zeiss Meditec, data on file.