

# Study Spotlight: ZEISS CLARUS UWF in Detection of Neovascular AMD



Seeing beyond

## Source



### Title

Retrospective analysis:  
Sensitivity and specificity of high-resolution wide field fundus imaging for detecting neovascular age-related macular degeneration



### Authors

Maiko Maruyama-Inoue, Yoko Kitajima, Shaheeda Mohamed, Tatsuya Inoue, Shimpei Sato, Arisa Ito, Shin Yamane, Kazuaki Kadonosono

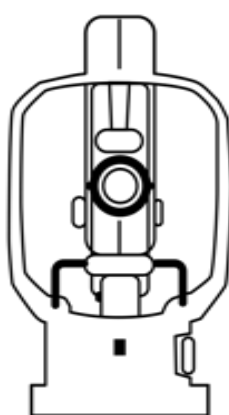


### Publication

Published August 21, 2020  
Research article in PLOS ONE  
<https://doi.org/10.1371/journal.pone.0238072>

## Methodology

### UWF systems compared



#### CLARUS 500 and Optos CA

Ultra-widefield fundus imaging

- Field of View comparison between CLARUS 133° FOV and Optos® California 200° FOV with Mydriasis
- The high-resolution of (CLARUS) 7.3 microns and high image quality that avoids eyelash and eyelid artifacts enables diagnosis of a variety of lesions in the retina.
- Eyelash artifacts with Optos® may prevent clear imaging of the inferior periphery


### Evaluation Criteria



#### Sensitivity and Specificity

in detection of neovascular AMD of UWF imaging to the reference standard (slit lamp biomicroscopy fundoscopy and SD-OCT)

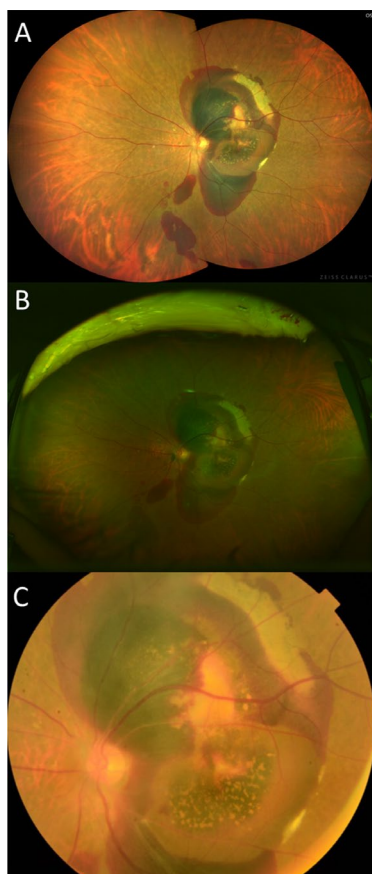
### Sample Size



#### 90 Eyes

of 73 consecutive patients with Neovascular AMD

## Results



**The sensitivity of CLARUS® in detection of neovascular AMD was significantly higher than Optos (P= 0.010) and higher than digital fundus images.**

**The specificity of the CLARUS, 89.5%, was equivalent to digital fundus imaging.**

